

Current state of the art of computer-guided implant surgery

JAN D'HAESE, JOHAN ACKHURST, DANIEL WISMEIJER, HUGO DE BRUYN & ALI TAHMASEB

Historical developments

The era of radiography began at the end of the 19th century when Wilhelm Roentgen discovered X-rays, which eventually resulted in a clinical technique used to evaluate internal anatomic structures in a noninvasive manner. A limitation was that only two-dimensional evaluation of mineralized structures was possible (32, 38). Sir Godfrey Newbold Hounsfield, an English electrical engineer who shared the 1979 Nobel Prize in Medicine with Allan McLeod Cormack, developed a method to acquire radiographs from different directions and/or angles, which could be digitally processed to a three-dimensional depiction (1, 28). This novel technique, originally called computerized axial tomography and later computerized tomography, was approximately 100 times more sensitive than conventional radiography and also allowed for the detection of soft tissues (27). At the end of the 1970s, several authors reported on the combined use of stereotaxic frames and computerized tomography scanning of the human head (7, 60). In addition, interactive software was developed and utilized to guide a probe precisely to a target that had been identified in a series of computerized tomography scans. This enabled treatment, for instance, of deep cerebral abscesses by aspiration after guiding a needle into a labeled cavity (51). In the late 1980s, different research groups developed and utilized several software packages to visualize the human head using computerized tomography images. This allowed the tip of an instrument to be mapped dynamically, in computerized tomography images, to the location corresponding to the point of interest. In 1992, an Ontario-based team used the first surgical navigation

unit for neurosurgery (21, 50). This frameless system, called the 'Viewing Wand', was developed as an adjunct to preoperative computerized tomography, magnetic resonance imaging and positron emission tomography, for surgical planning before, and navigation during, the operation. The Viewing Wand represented a milestone in guided surgery as it combined conventional surgical approaches with virtual reality in order to plan the surgical procedure in advance and to use the planned intervention as a guide during the actual surgery. In comparison with stereotaxic surgery, the main advantage of the Viewing Wand technique was that neither constant intra-operative scanning nor the fixation of a cumbersome frame to a patient's head was necessary. The primary clinical benefits of the Viewing Wand were the significantly improved surgical navigation and clinical safety for the patient during the surgical intervention itself (21). Also, the localization and size of the incision, craniotomy and corticotomy, as well as the extent of the surgical resection, benefited from the use of this surgical approach. However, stereotaxic surgery was still needed to localize the source of small, deep-seated, targets in procedures such as thalamotomy and pallidotomy (50). Shortly after the introduction of the so-called frameless stereotaxic surgery, new opportunities were created for this technique as it was discovered that it could be used for anatomic navigation in upper cervical spine surgery (45). In the following 5 years, several companies introduced similar products of surgical navigation and the technology also became applicable for other surgical procedures, such as head neck surgery (25), sinus surgery (12), spinal surgery (45) and arthroscopy (18). The surgical paradigm of exposing the tissues in order to obtain a

better view of the surgical area became irrelevant and, in fact, to an extent irresponsible in certain situations. In the early 2000s, surgical navigation became the standard of care in neurosurgery and was starting to become increasingly popular in sinus and spinal surgery.

Surgical navigation

Prosthetically driven implant surgery has been a subject of fundamental interest to the dental profession. Correct implant positioning has obvious advantages, such as favorable esthetic and prosthetic outcomes, long-term stability of peri-implant hard and soft tissues as a result of simple oral hygiene and the potential to ensure optimal occlusion and implant loading (8–10). Moreover, correct positioning of the implant enables the final prostheses to be optimally designed and makes it possible to devise and fabricate retrievable screwretained suprastructures, thereby avoiding nonretrievable cemented restorations (36). Consequently, all of these factors may contribute to the long-term success of dental implants. Furthermore, various requirements, such as the desired interimplant distance, tooth-to-implant distance, implant depth and other aspects, have made virtual implant planning an important tool when aiming for optimal treatment success (26, 56).

In 1988, Columbia Scientific, Inc (Glen Burnie, MD, USA) introduced three-dimensional dental software, which converted computerized tomography axial slices into reformatted cross-sectional images of the alveolar ridges for diagnosis and evaluation. Consequently, in 1991, a combination software, ImageMaster-101, was introduced, which provided the additional feature of placement of graphic images of dental implants on the cross-sectional images. The first version of SimPlant, produced by Columbia Scientific in 1993, allowed placement of virtual implants of exact dimensions on cross-sectional, axial and panoramic views of computerized tomography images. SimPlant 6.0 (Columbia Scientific 1999) added the creation of a three-dimensional reformatted image surface rendering to the software. In 2002, Materialise (Leuven, Belgium) purchased Columbia Scientific and introduced the technology for drilling osteotomies to an exact depth and direction through a surgical guide. Since then, several software, rapid prototyping and implant companies have introduced their own software and surgical guide modalities to allow a guided surgical approach. Figure 1 shows the

applicability of cone-beam computerized tomography imaging in conjunction with a virtual planning program.

Generally, two types of guided implant surgery protocols – static and dynamic – are described in the literature. The static approach refers to the use of a static surgical template. This reproduces the virtual implant position directly from computerized tomographic data to a surgical guide, which does not allow intra-operative modification of the implant position (31,55). With the static systems, the planned implant location is usually transferred to the surgical template by a specially designed drilling machine (9). Another option, called the stereolithographic method, uses specifically designed software to design virtually the surgical stent and afterwards fabricate it using polymerization of an ultraviolet-sensitive liquid resin (10) (Figs 2 and 3). The first dynamic guided surgery systems were introduced to the field of implant dentistry at the beginning of the year 2000. The dynamic approach, also called navigation, refers to the use of a surgical navigation system that reproduces the virtual implant position directly from computerized tomographic data and allows intra-operative changes of the implant position (31, 55). These systems are based on motion-tracking technology that allows real-time tracking of the dental drill and the patient throughout the entire surgery (Fig. 4).

The introduction of cone-beam computerized tomography scanning, in combination with three-dimensional imaging tools, has led to a major breakthrough in virtual implant treatment planning. Cone-beam computerized tomography scanners use lower radiation doses compared with conventional computerized tomography scanners (37). Additionally, cone-beam computerized tomography scanners are much smaller and less expensive than conventional computerized tomography scanning machines; this allows the private practitioner to buy and install a cone-beam computerized tomography machine in his own clinical setting. In combination with implant planning software, the use of cone-beam computerized tomography data has made it possible to plan virtually the ideal implant position, while taking the surrounding vital anatomic structures and future prosthetic requirements into consideration. Consequently, this process ultimately results in the transfer of the planned virtual implant position from the computer to the patient. In addition, intra-oral scanning devices have recently started to contribute considerably to these novel treatment modalities with respect to treatment planning (29). By

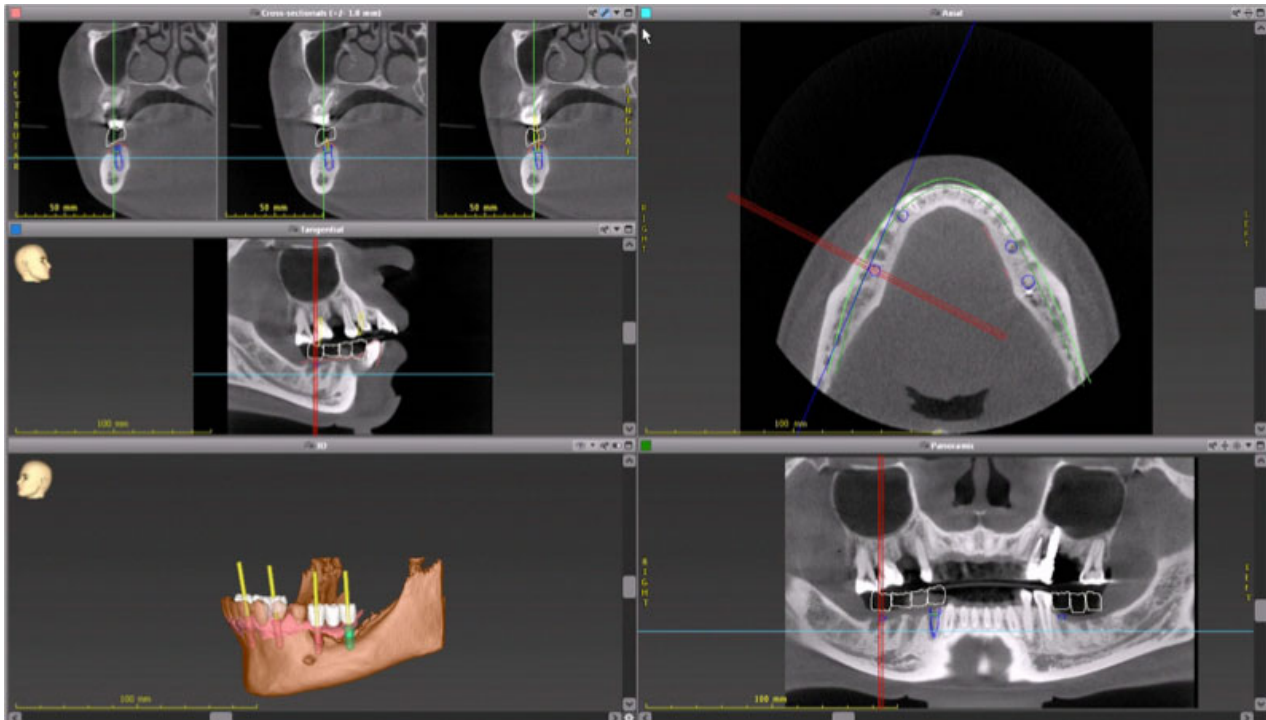


Fig. 1. Virtual implant planning (Codiagnostix, Dentalwings) in the posterior mandible, illustrating different cross-sections, panoramic views and three-dimensional imaging of a scanned subject.

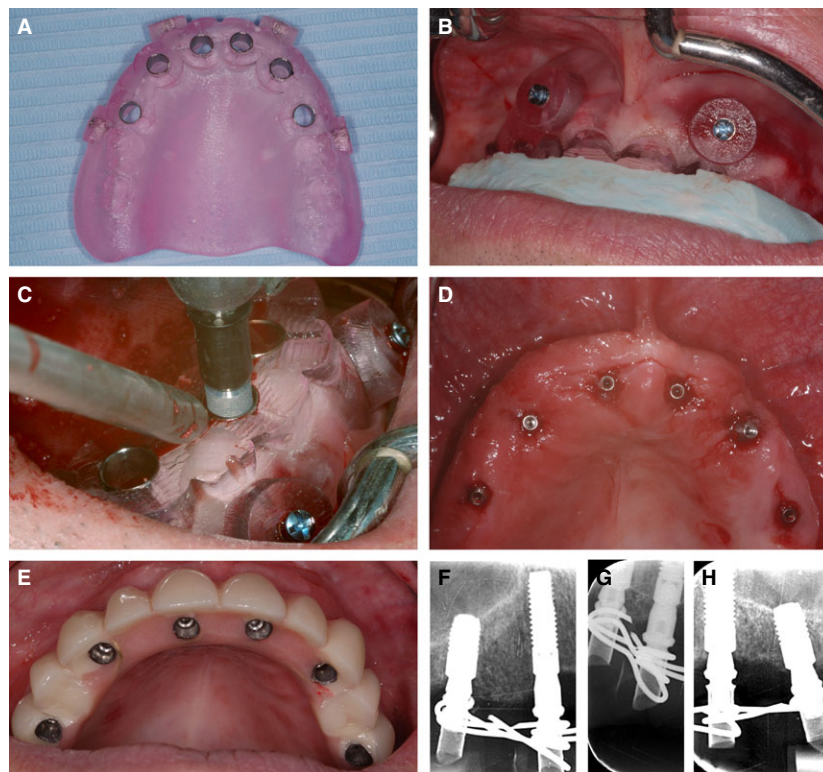


Fig. 2. Clinical example illustrating the treatment protocol for tissue-supported guidance. (A) Stereolithographic guide with equally distributed fixation screws. (B) Fixation of the guide using an intermaxillary putty index. (C) Guided installation with copious irrigation. (D) All

implants installed with uni-abutment installed on top. (E) Fibre-reinforced acrylic screw-retained bridge seated. (F-H) Peri-apical radiographs on implants, abutments and bridge *in situ*.

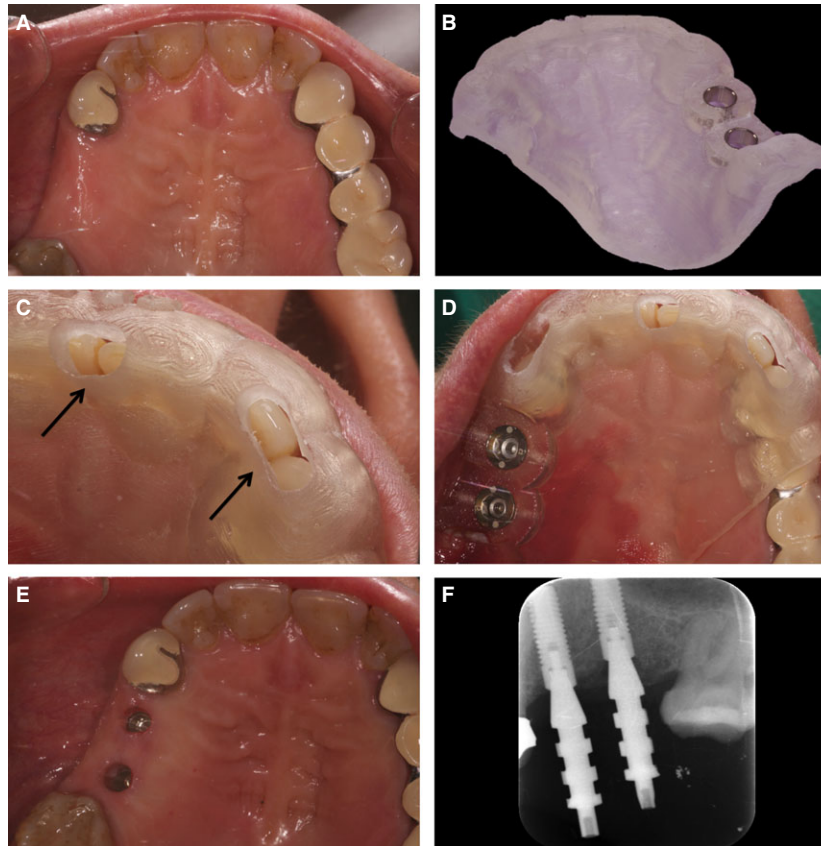


Fig. 3. Clinical example illustrating the treatment protocol for tooth-supported guidance. (A) Preoperative view of the maxilla. (B) Dentally supported stereolithographic guide. (C) Inspection windows are used to confirm proper seating

of the guide. (D) Depth-calibrated implant mounts. (E) Postoperative view of installed implants. (F) Impression copings 3 months postoperatively.

superimposing images of recognizable structures (e.g. teeth) obtained from cone-beam computerized tomography and intra-oral scanning, a more realistic digital view of the dental hard and soft tissues of a patient is created. A digital set-up can also be added to this data set, to assist dental professionals to execute the planning in relation to the future prosthetic restoration. Yet, while technology continuously improves, there are still some major issues that need to be taken into account when these techniques are implemented to treat patients (55).

Static computer-assisted guidance

Guide production

Guide production is model-based, and guides are made in the dental laboratory or processed using computer-aided design/computer-aided manufacturing through milling or printing. Model-based systems use a laboratory-based guide-production device. The basis for surgical template fabrication is the template

plan provided by the planning software. This plan contains four parameters for the spatial position of each implant and depth information for the placement of the surgical guide sleeves. The scan template is fitted on the master model that represents the patient. In accordance with the preferences of the clinician and dental technician, the scan template contains information about the desired prosthetic outcome and the soft-tissue architecture. After verification of all parameters, sleeve bed preparation and surgical sleeve placement are carried out using the drilling arm. The main disadvantage of this approach is the number of nondigital steps required to design and produce the surgical guide, together with its sensitivity to the associated human errors that can occur during different steps of the procedure.

Another way to create surgical guides is by using a rapid prototyping technique or stereolithographic technology. Based on three-dimensional imaging and a three-dimensional design, the guides are produced using photopolymerization techniques and are currently commonly produced commercially by many

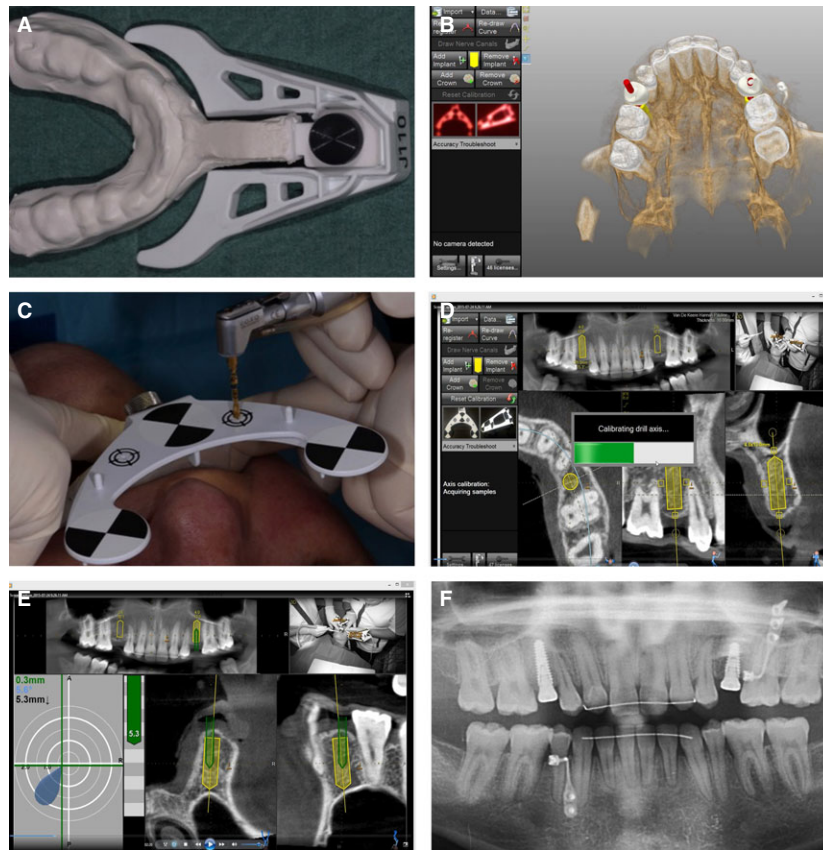


Fig. 4. Clinical example illustrating the treatment protocol with dynamic guided surgery (Navident, Canada). A. Thermoplastic stent (Navistent TM) connects the radiographic marker with the residual teeth B. Digital interface allows a

implant providers. The most recent development in digital production of surgical guides is based on the superimposition of digital computerized tomography data and intra-oral scanning data. Therefore, mutual landmarks on both digital images, such as part of the teeth, are required. The actual guides are designed and fabricated using computer-aided design/computer-aided manufacturing technology with the use of printing or milling devices. These novel approaches improve positioning and accuracy in terms of the relationship between virtually planned and real-life insertion of the implant, especially when using tooth-supported surgical guides (24, 43, 55). However, a larger number of clinical investigations are needed to support this statement.

Guide support

Various surgical guide designs are available that differ either in the type of support or in the way that they are positioned. In general, the following types of surgical guides are described in the literature, based on their supporting surfaces:

prosthetically driven implant surgery C + D. Before using a new drill, a calibration procedure is necessary E. Osteotomy preparation can be seen in real time F. Post-op CBCT after implant installation.

- Tooth-supported surgical guides: the surgical guide is placed on the remaining teeth.
- Mucosa-supported surgical guides: the surgical guide is positioned on top of the mucosa. This is mostly used in fully edentulous patients.
- Bone-supported surgical guide: the surgical guide is placed on the bone after opening a mucoperiosteal flap. Applicable in patients in whom more extensive (bone) surgery is required.
- Special supported, (mini) implant, pin-supported surgical guides: the surgical guide is attached to implants inserted before or during the actual implant surgery.

A systematic review from the 5th International Team for Implantology Consensus Conference (55) concluded that, compared with other types of guide, the bone-supported surgical guides showed the highest inaccuracy. Additionally, Tahmaseb et al. (53) showed that a high level of accuracy could be achieved when reference mini-implants were used to support the computerized tomography scan template and the final surgical guide. This could result in immediate loading of the installed implants using a prefabricated restoration (Fig. 5).

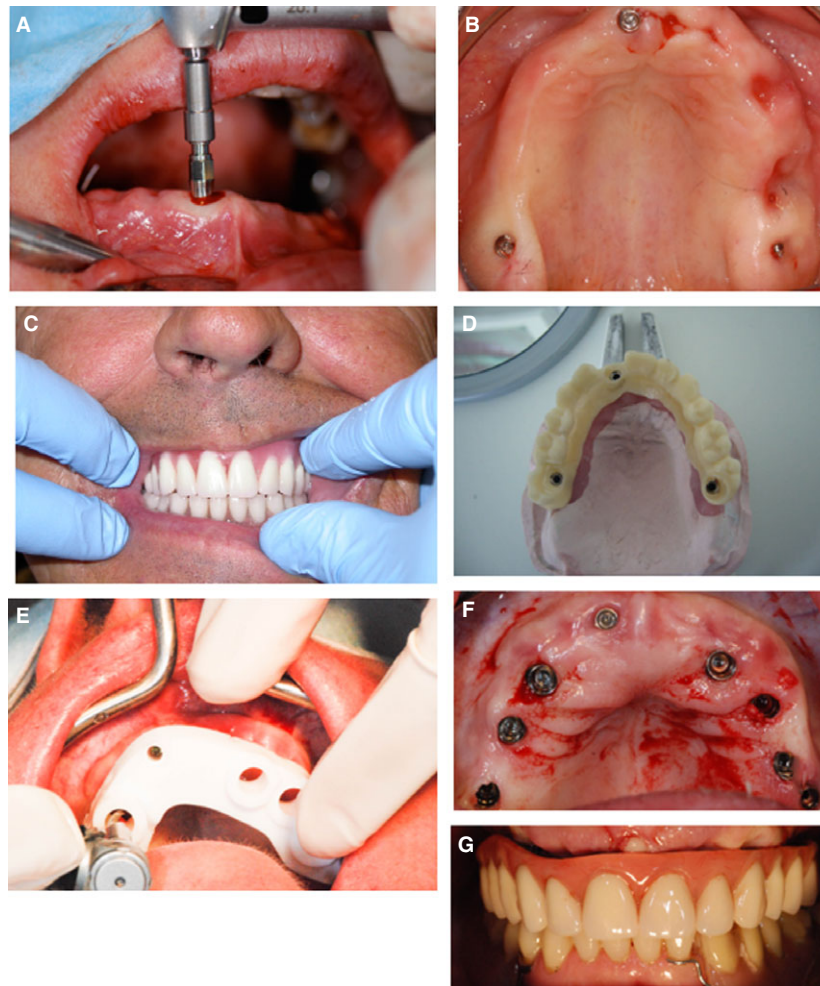


Fig. 5. Clinical example of guided surgery and immediate loading using pre-installed mini-implants. (A, B) Insertion of mini-implants. (C) Prosthetic steps to prepare the final prosthetic set-up. (D) Duplicating the set-up in radiopaque material to use it during the cone-beam computerized

tomography data acquisition. (E) Insertion of the drill guide and executing the osteotomy. (F) Flapless implant insertion. (G) Attachment of the prefabricated provisional superstructure.

The level of guidance

Different treatment protocols using guided surgery have been described in the literature. Some systems require several consecutive guides to cope with an increasing drill diameter during surgery (20), while others use one guide with different adjustable drill handles (53) (Fig. 6). Moreover, some systems allow guided osteotomy preparation and implant placement (fully guided protocol), while others only allow guided osteotomy, resulting in a freehand implant installation. The findings of the 5th International Team for Implantology Consensus Conference concluded that the so-called fully guided protocols, with guided implant placement included, performed more accurately compared with partially guided systems in which only the osteotomy is guided while final implant placement is performed freehand (55).

Dynamic computer-assisted guidance

Because of the uncomplicated handling and lower investment costs, the static technique is widely used as the method of choice when guided surgery is indicated. Currently, most major implant brands have their own stereolithographic guided surgery system, based on the same basic principle. Hence, the static approach is used more frequently (10) than the dynamic approach but both show equal failure rates (10).

In a case series study, it was reported that less than 1 mm of mean linear deviation and angular deviation of less than 4° might be attainable, although the technique was vulnerable to technical errors (36). An interesting report published data comparing a conventional freehand method of osteotomy preparation and a navigation guided drilling procedure (56). The

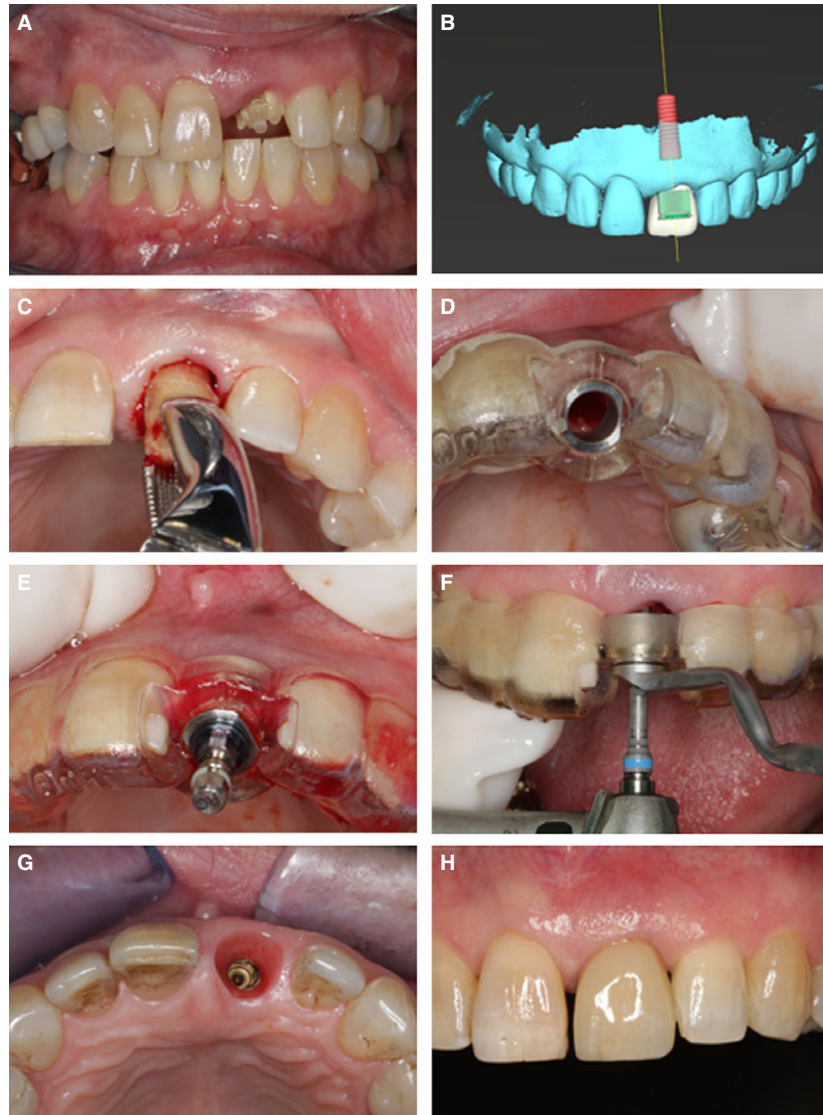


Fig. 6. Clinical example illustrating the treatment protocol for tooth-supported guidance. (A) Failed central incisor. (B) Computer planning for implant position. (C) Atraumatic extraction. (D) Guide seated by dental retention and

stability. (E) Osteotomy preparation until stop mount. (F) Utilization of interchangeable drill keys. (G) Healing with temporary crown to design emergence profile. (H) End result.

authors showed that the differences between the two methods were significantly in favor of the navigation protocol. In another publication, a comparison was made between static and dynamic guided surgery, and it was concluded that static guided surgery was associated with fewer errors than real-time navigation (26), while other authors (31) could not find any statically significant differences. An interesting finding was also that navigated flapless transmucosal interforaminal implant placement was found to be a precise, predictable and safe procedure in patients with a smooth, wide and regular mandibular ridge compared with a more irregular bony architecture that resulted in a more complicated, and less accurate, implant placement (55).

Another relevant factor explaining why navigation surgery initially was not attractive was the fact that, at that time, the cone-beam computerized tomography technique was not popular in daily practice. This prevented the dentist from obtaining high-quality computerized tomography data at a low radiation dose. Additionally, these dynamic navigation systems were also too expensive and complicated for the private practitioner, especially when compared with cheaper stereolithographic alternatives. Finally, navigation systems were too cumbersome, complicated and fragile to be reliable and easily applicable in daily practice. Accordingly, most of the first-generation dental navigation systems slowly disappeared from the market. As a result of the introduction of more

affordable and smaller cone-beam computerized tomography scanners, one of the major disadvantages of dynamic navigation was eliminated. Together with evolution toward the so-called fourth industrial revolution, usability and reliability of more complex computerized systems have been greatly improved. This digital revolution is characterized by a fusion of technologies blurring the lines between the physical world and virtual reality. Dental implant navigation benefited from these improvements and evolved toward new dynamic navigation devices that use real-time tracking technology. This resulted in a simplified workflow because scanning, planning and implant placement could be carried out in a single visit and required fewer time-consuming image-registration procedures. Moreover, fewer additional tools or surgical sets were required, resulting in an open-sourced system, enabling the surgeon to use his favorite implant system in his/her familiar environment.

Flapless or flap surgery

As in general medicine, also implant dentistry has evolved toward increased use of minimally invasive procedures. In this respect, guided implant surgery is a valuable adjunct. A flapless procedure is defined as a dental implant installed through the mucosal tissues without reflecting a mucoperiosteal flap or minimal reflection of the flap. Implant installation can be performed either freehand after drilling through the soft tissue or by using a surgical guide. The advantage of the minimal surgical procedure lies in preservation of the blood circulation in the soft tissues, which may affect the soft-tissue architecture (47). In a systematic review, Cosyn et al. (15) concluded that a flapless approach reduced bone loss but also enhanced papilla regrowth and hence the esthetic outcome of single implants. Furthermore, a flapless approach avoids elevation of the mucoperiosteal flap and keeps the periosteum in contact with the bone and the suprapariosteal plexus intact, hence preserving the osteogenic potential and the blood supply to the underlying bone and/or implant. Bone denudation causes increased bone loss (52). Some clinical studies have shown that marginal bone around dental implants is preserved with flapless surgery (3, 4, 44). On the other hand, Sennerby et al. (48) concluded that less bone loss occurred after one-piece implants were placed with conventional flap elevation together with a delayed loading protocol when compared with the flapless approach. Other studies, using a more

conventional approach, did not show any difference (6,14).

The flapless approach is beneficial to patients because considerably less postoperative morbidity and discomfort has been reported compared with open flap surgery (4, 22, 34, 41). As a result, patients are more likely to undergo flapless surgery (2, 58). From a clinical perspective, minimal surgical intervention may allow the treatment of anxious or medically compromised (such as those undergoing treatment with anticoagulants or bisphosphonates) patients. It also offers the possibility of using a provisional restoration, enhancing soft-tissue healing and immediately restoring function and esthetics. As a result, the patient can resume normal oral-hygiene measures immediately (47). In addition, the quality and quantity of the surrounding soft tissue must be taken into consideration when choosing between flapped or flapless surgery. In some cases, flapless surgery may result in the removal of too much well-needed keratinized soft tissue around the implants. However, when guided surgery is applied, flap design should be as minimal as possible and must be well adapted to the clinical situation. Brodala et al. (6) stated that flapless surgery appears to be a plausible treatment modality for implant placement, demonstrating both efficacy and clinical effectiveness. However, these data are derived from short-term studies with a mean follow-up interval of 19 months, and a successful outcome with this technique is dependent on advanced imaging, clinical training and surgical judgment.

Flapless guided or freehand surgery

Several clinical trials evaluated the outcome of dental implants when placed with a flapless approach. Becker et al. (5) used a split-mouth design in an experiment on dogs and showed, using histomorphometry, that the composition of the tissues were not different between flapless or flapped surgery. Implants placed after punching the mucosal tissues with a drill, without flaps and additionally less effective direct irrigation in the bone during implant placement, showed the same degree of osseointegration and no adverse reactions. In a retrospective study reporting on flapless surgery, the survival, up to 10 years, of 770 implants installed in 359 patients was 93.6%. Implants were installed in mandibles and maxillae, and the survival rate was influenced by the surgeons' learning curve (11). Rocci et al. (44) installed 97 implants with turned surfaces in 46

maxillae for single or partial rehabilitations. After 3 years of prosthetic loading, the cumulative survival rate was 91% with a mean bone loss of 1.5 mm. The failure rate was higher in sites implanted immediately after tooth extraction. Others reported a failure rate of 25% of immediately loaded single implants installed with flapless surgery compared with no failures for a delayed loading group (42). Despite a higher failure rate, they reported similar esthetic results with both techniques (42). Single implants installed in a one-stage flapless surgery without the use of computer-assisted guides showed the same clinical success as those installed using conventional one-stage flap surgery. Overall, implant survival was 100% and stable bone conditions, indicative of a good long-term prognosis, were reported (19). However, the pragmatic approach in the latter study involved nonrandomized case selection and only cases with predicted good outcome were chosen for the flapless approach and treatment by an experienced periodontist. Nevertheless, within the limitations of single-tooth restorations and within the 3–4 years of loading time, it seems that flapless surgery in healed bone with delayed loading offers a good alternative to conventional surgery.

A disadvantage of flapless freehand surgery is that the true topography of the underlying available bone cannot be observed. Clinical palpation alone is not advisable in complex cases because thick epithelium and thick mucosa may hide a narrow ridge. There is a risk of unwanted perforation of the bone and this may lead to esthetic problems or even implant loss. The potential risk for perforation was evaluated in a preclinical study in which flapless freehand surgery was performed on models. Very often perforations through the crest and on the crest were observed because clinicians could not fully implement the morphology of the available bone as visualized on two-dimensional and even on three-dimensional radiographs, to the level of the real patient (58). Also, unwanted perforations and improper implant location have been reported as complications (11). It seems that flapless freehand surgery can only be advocated in selected and appropriately planned cases by experienced surgeons and when there is adequate bone volume. A computer-guided approach may overcome these drawbacks, as suggested by Tahmaseb et al. (55). They concluded, based on a systematic review, that the level of accuracy was satisfactory when flapless guided surgery was applied using nonbone-supported surgical guides and a good clinical outcome was presented.

Immediate loading and guided surgery

Knowing the implant position before actual implant placement opened up the possibility of attaching a prefabricated and immediately loaded suprastructure on the day of surgery (30, 39, 54), which has obvious advantages for both patients and clinicians. The literature provides strong evidence that immediate loading of dental implants with a fixed provisional prosthesis in both the edentulous mandible and maxilla is as predictable as early and conventional loading (23). However, prefabrication of the final prosthetic restoration before surgery cannot be assumed to be a foolproof concept. Komiyama et al. (33) stated, in a clinical study on guided surgery, that although the patients' postoperative discomfort, such as swelling and pain, was almost negligible compared with conventional protocols, the occurrence of surgical and technical complications was high. They concluded that this method must still be regarded to be in an exploratory phase. However, Tahmaseb et al. (54) showed that when they rigorously followed their clinical protocol, production and surgical technique, in conjunction with use of reference implants or devices, a high level of accuracy was achieved in the use of prefabricated restorations. Another approach is to fabricate a provisional bridge that is screwed or cemented to provisional abutments after surgery in order to minimize the risk of misfit, as described for freehand implant surgery and immediate loading (17). The provisional bridge is then replaced with a permanent bridge after healing.

Clinical outcomes of guided surgery

Implant survival

Since 2010, several reviews, including systematic reviews, assessed the accuracy of flapless guided surgery in clinical studies. In general, it can be concluded that the implant survival rate ranges from 91% to 100%. In a review performed by Tahmaseb et al. (55), as part of the 2013 International Team for Implantology consensus conference, 14 survival and 24 accuracy studies were included. The overall implant survival rate was reported to be 97.3% based on 1941 implants. However, in 36.4% of cases, intra-operative or prosthetic complications were reported. Those included template fractures during surgery, change of

plan because of limited implant stability, need for nonplanned grafting, prosthetic screw loosening, misfit and prosthesis fractures. Based on the meta-analysis, the authors concluded that there is, as yet, no evidence suggesting that computer-assisted surgery is superior to conventional surgery in terms of safety, outcome, morbidity or efficiency. D'haese et al. (16) reviewed a total of 31 clinical studies, whereof 10 reported on accuracy. They concluded that guided surgery yields a more accurate placement than does freehand implant placement. Nevertheless, from both cadaver and clinical studies it was obvious that guided surgery is far from accurate. Deviations at the shoulder of the implant hamper correct fit of the suprastructures and could require extensive adaptations in occlusion and articulation. They suggest that a 2-mm safety zone should be respected apically to the planned position to avoid critical anatomic structures.

There are a few reviews assessing implant survival with flapless and guided surgery. Voulgarakis et al. (59) evaluated the outcome of three treatment protocols, namely freehand surgery, guided surgery with a prosthetic stent and guided surgery with stereolithographic computer-guided navigation. They included 23 studies with a prospective or retrospective design but randomized control trials were not available and the significant heterogeneity of the studies excluded a meta-analysis. Lin et al. (35) focused on the clinical results of flapless surgery and performed a meta-analysis on implant survival and peri-implant bone loss based on 12 studies, including seven randomized controlled clinical trial. The meta-analysis of Moraschini et al. (40) reported on survival, crestal bone and complications with guided surgery based on 13 studies. The implant survival, as reported in the three reviews, ranges from 89% to 100%, albeit that the follow-up time is rather short, ranging from 6 to 48 months. It can be concluded, based on a total of 35 clinical trials, that freehand surgery is comparable with guided flapless surgery in terms of implant survival, marginal bone remodeling and peri-implant variables.

Accuracy

Computer-guided implant procedures have often been recommended in cases with critical anatomic situations (e.g. an implant to be placed adjacent to the mandibular nerve). Therefore, knowledge of the potential maximal implant deviation of these systems is highly relevant to daily clinical practice and has to be taken into consideration. The data analyzed in the

proceedings of the 5th International Team for Implantology Consensus Conference (55) on computer-guided surgery showed an inaccuracy at the implant entry point (between the planned implant position and the position at which the implant was inserted) of, on average, 1.12 mm (maximum 4.5 mm) and an inaccuracy of, on average, 1.39 mm at the apex of implants (maximum 7.1 mm). However, the maximal deviations measured occurred in two studies (13, 20) and were far outside the acceptable range. These outliers might be related to external factors. For example, Di Giacomo et al. (20) proposed that movements of the surgical guide might cause differences in the deviation during implant preparation. This group suggested further improvements that could provide better template stability during surgery for unilateral bone-supported and nontooth-supported templates. Moreover, sandblasted with a large grit acid-etched (computer-assisted manufacture) guides had slightly better accuracy than did laboratory guides (noncomputer-assisted manufacture), although the number of cases was significantly lower for the noncomputer-assisted manufacture group (171 implants vs. 1,569 implants). Furthermore, the supporting structures have a significant impact on accuracy. Tahmaseb et al. (53) showed that guides supported by mini-implants provided high accuracy in implant positioning. This might be a result of the reproducibility of the template position during the acquisition of radiographic data and during implantation. This is especially the case in fully edentulous patients in whom no other references are available. Moreover, clinical studies have shown a statistically significant lower accuracy for bone-supported guides compared with other modes of support. These results could also explain why the flapped approaches had lower accuracy than the flapless ones, as the majority of treatments in which a flap is raised used bone-supported surgical guides.

Complications

Various series of early surgical and prosthetic complications have been reported in the literature when computer-guided surgery is applied (31, 46, 55). The most frequently reported complications are related to intra-operatively broken stereolithographic surgical guides (Fig. 7), alterations to the surgical plan, early implant loss because of lack of primary stability and prosthetic fracture. Schneider et al. (46) reported an incidence of 9.1% for early surgical complications and an incidence of 18.8% for early prosthetic complications. These complications are associated with

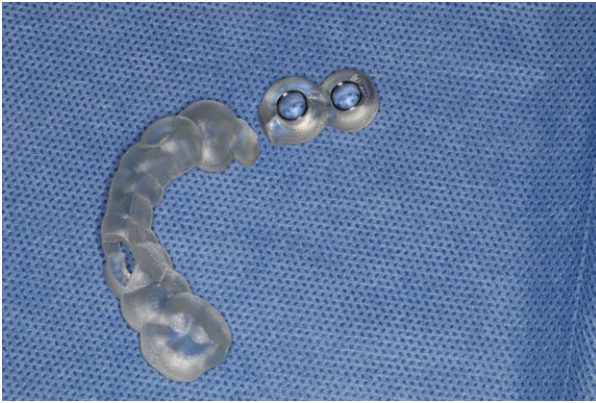


Fig. 7. Broken guide plate during the surgical procedure.

incorrect implant placement or deviations from the originally planned location. This occurs especially when stereolithographic guided surgery is followed by immediate provisionalization with a previously prepared fixed bridge. Additionally, late prosthetic complications were found in 12% of patients. A meta-analysis revealed that the mean horizontal deviations were 1.1–1.6 mm but with higher maximal deviations. In particular, the higher deviations may cause nerve disturbances, may damage anatomically vital structures (such as sinuses and nose) and additionally lead to prosthetic complications.

New developments

Novel technical developments in digital dental technology have indeed had an impact on computer-guided implant surgery. New technological advancements made in software and hardware have significantly improved data acquisition and processing (i.e. cone-beam computerized tomography images provide a more realistic overview of the bony and anatomic structures). For instance, information on bone density predicts the stability of implants already at the virtual planning stage (49). Moreover, intra-oral scanners can capture the morphology of oral soft tissues and the structure of the teeth. The combination of intra-oral scanners and cone-beam computerized tomography images, by mutual superimposing and use of planning software, provides an almost complete three-dimensional representation of soft and hard tissues. In addition, novel planning software allows creation of a digital wax-up of the future prosthetic plan, which can be viewed and improved if needed. Based on this complete data set, the design and fabrication of computer surgical guides can proceed with improved precision, which can result in

more accurate implant placement than obtained with previous techniques. Furthermore, novel production techniques to fabricate the surgical guides are evolving extremely rapidly. Milling and three-dimensional printing technologies have replaced laboratory-based and sandblasted large grit acid-etched technology, which might improve the accuracy of implant placement and related treatments.

Conclusions

Based on the available literature it can be concluded that no decisive evidence yet exists which suggests that computer-assisted surgery is superior to conventional procedures in terms of safety, treatment outcomes, morbidity or efficiency. High levels of inaccuracies are reported where these techniques were applied. This imprecision seems most significant when bone-supported guides are used. The accuracy of these systems depends on all the cumulative and interactive errors involved, from data-set acquisition to the surgical procedure. However, one can predict that new developments (such as digital impression) and improved technologies (such as real-time navigation and improved merging of radiographic and clinical data) will have a positive impact on guided surgery. When all the new developments are taken into account, there is still no substitute for proper case selection, patient preparation and basic surgical planning and execution. Long-term clinical data and randomized clinical trials are needed to identify and understand the different factors influencing the accuracy of these techniques as well as their mutual interaction.

References

1. Ambrose J, Hounsfield GN. Computerized transverse axial tomography. *Br J Radiol* 1973; **46**: 148–149.
2. Arisan V, Karabuda CZ, Ozdemir T. Implant surgery using bone- and mucosa supported stereolithographic guides in totally edentulous jaws: surgical and post-operative outcomes of computer-aided vs. standard techniques. *Clin Oral Implants Res* 2010; **21**: 980–988.
3. Becker W, Goldstein M, Becker BE, Sennerby L. Minimally invasive flapless implant surgery: a prospective multicenter study. *Clin Implant Dent Relat Res* 2005; **7**: 21–27.
4. Becker W, Goldstein M, Becker BE, Sennerby L, Kois D, Huipel P. Minimally invasive flapless implant placement: follow-up results from a multicenter study. *J Periodontol* 2009; **80**: 347–352.
5. Becker W, Wikesjo UM, Sennerby L, Qahash M, Hujuel P, Goldstein M, Turkyilmaz L. Histologic evaluation of

- implants following flapless and flapped surgery: a study in canines. *J Periodontol* 2006; **77**: 1717–1722.
6. Brodala N. Flapless surgery and its effect on dental implant outcomes. *Int J Oral Maxillofac Implants* 2009; **24**: 118–125.
 7. Brown RA. A stereotactic head frame for use with CT body scanners. *Invest Radiol* 1979; **14**: 300–304.
 8. Buser D, Bornstein MM, Weber HP, Grütter L, Schmid B, Belser UC. Early implant placement with simultaneous guided bone regeneration following single-tooth extraction in the esthetic zone: a cross-sectional, retrospective study in 45 subjects with a 2- to 4-year follow-up. *J Periodontol* 2008; **79**: 1773–1781.
 9. Buser D, Halbritter S, Hart C, Bornstein MM, Grütter L, Chappuis V, Belser UC. Early implant placement with simultaneous guided bone regeneration following single-tooth extraction in the esthetic zone: 12-month results of a prospective study with 20 consecutive patients. *J Periodontol* 2009; **80**: 152–162.
 10. Buser D, Wittneben J, Bornstein MM, Grütter L, Chappuis V, Belser UC. Stability of contour augmentation and esthetic outcomes of implant-supported single crowns in the esthetic zone: 3-year results of a prospective study with early implant placement post extraction. *J Periodontol* 2011; **82**: 342–349.
 11. Campelo LD, Camara JR. Flapless implant surgery: a 10-year clinical retrospective analysis. *Int J Oral Maxillofac Implants* 2002; **17**: 271–276.
 12. Carpenter S. Image-guided sinus surgery: navigation without road maps. *Semin Perioper Nurs* 2000; **9**: 155–162.
 13. Cassetta M, Giansanti M, Di Mambro A, Calasso S, Barbato E. Accuracy of two stereolithographic surgical templates: a retrospective study. *Clin Implant Dent Relat Res* 2013; **15**: 448–459.
 14. Chrcanovic BR, Albrektsson T, Wennerberg A. Flapless versus conventional flapped dental implant surgery: a meta-analysis. *PLoS One* 2014; **9**: e100624.
 15. Cosyn J, Hoogde N, De Bruyn H. A systematic review on the frequency of advanced recession following single immediate implant treatment. *J Clin Periodontol* 2012; **39**: 582–589.
 16. D'haese J, Van de Velde T, Komiyama A, Hultin M, De Bruyn H. Accuracy and complications using computer-designed stereolithographic surgical guides for oral rehabilitation by means of dental implants: a review of the literature. *Clin Implant Dent Relat Res* 2012a; **14**: 321–335.
 17. D'haese J, Van De Velde T, Elaut L, De Bruyn H. A prospective study on the accuracy of mucosally supported stereolithographic surgical guides in fully edentulous maxillae. *Clin Implant Dent Relat Res* 2012b; **14**: 293–303.
 18. Dario P, Carrozza MC, Marcacci M, D'Attanasio S, Magnami B, Tonet O, Megali G. A novel mechatronic tool for computer-assisted arthroscopy. *IEEE Trans Inf Technol Biomed* 2000; **4**: 15–29.
 19. De Bruyn H, Atashkadeh M, Cosyn J, Van de Velde T. Clinical outcome and bone preservation of single TiUnite implants installed with flapless or flap surgery. *Clin Implant Dent Relat Res* 2011; **13**: 175–183.
 20. Di Giacomo G, Cury PR, de Araujo NS, Sendyk WR, Sendyk CL. Clinical application of stereolithographic surgical guides for implant placement: preliminary results. *J Periodontol* 2005; **76**: 503–507.
 21. Dyer PV, Patel N, Pell GM, Cummins B, Sandeman DR. The ISG viewing wand: an application to atlanto-axial cervical surgery using the Le fort I maxillary osteotomy. *Br J Oral Maxillofac Surg* 1995; **33**: 370–374.
 22. Fortin T, Bosson JL, Isidori M, Blanchet E. Effect of flapless surgery on pain experienced in implant placement using an image-guided system. *Int J Oral Maxillofac Implants* 2006; **21**: 298–304.
 23. Gallucci GO, Benic GI, Eckert SE, Papaspyridakos P, Schimmel M, Schrott A, Weber HP. Consensus statements and clinical recommendations for implant loading protocols. *Int J Oral Maxillofac Implants* 2014; **29**: 287–290.
 24. Geng W, Liu C, Su Y, Li J, Zhou Y. Accuracy of different types of computer-aided design/computer-aided manufacturing surgical guides for dental implant placement. *Int J Clin Exp Med* 2015; **8**: 8442–8449.
 25. Gunkel AR, Freysinger W, Thumfart WF. Experience with various 3-dimensional navigation systems in head and neck surgery. *Arch Otolaryngol Head Neck Surg* 2000; **126**: 390–395.
 26. Hermann JS, Schoolfield JD, Schenk RK, Buser D, Cochran DL. Influence of the size of the microgap on crestal bone changes around titanium implants. A histometric evaluation of unloaded non-submerged implants in the canine mandible. *J Periodontol* 2001; **72**: 1372–1382.
 27. Hounsfield GN. Computerized transverse axial scanning (tomography). 1 Description of system. *Br J Radiol* 1973; **46**: 1016–1022.
 28. Hounsfield GN. Computed medical imaging. *Science* 1980; **210**: 22–28.
 29. Joda T, Gallucci GO. The virtual patient in dental medicine. *Clin Oral Implant Res* 2014; **26**: 725–726.
 30. Johansson B, Friberg B, Nilson H. Digitally planned, immediately loaded dental implants with prefabricated prostheses in the reconstruction of edentulous maxillae: a 1-year prospective, multicenter study. *Clin Implant Dent Relat Res* 2009; **11**: 194–200.
 31. Jung R, Schneider D, Ganeles J, Wismeijer D, Zwahlen M, Hämmerle CH, Tahmaseb A. Computer technology applications in surgical implant dentistry: a systematic review. *Int J Oral Maxillofac Implants* 2009; **24**: 92–109.
 32. Keevil GM. The roentgen rays. *Br Med J* 1833; **1896**: 433–434.
 33. Komiyama A, Klinge B, Hultin M. Treatment outcome of immediately loaded implants installed in edentulous jaws following computer-assisted virtual treatment planning and flapless surgery. *Clin Oral Implants Res* 2008; **19**: 677–685.
 34. Landázuri-Del Barrio RA, Cosyn J, De Paula WN, De Bruyn H, Marcantonio E Jr. A prospective study on implants installed with flapless-guided surgery using the all-on-four concept in the mandible. *Clin Oral Implants Res* 2013; **24**: 428–433.
 35. Lin GH, Chan HL, Bashutski JD, Oh TJ, Wang HL. The effect of flapless surgery on implant survival and marginal bone level: a systematic review and meta-analysis. *J Periodontol* 2014; **85**: e91–e103.
 36. Linkevicius T, Puisys A, Vindasiute E, Linkeviciene L, Apse P. Does residual cement around implant-supported restorations cause peri-implant disease? A retrospective case analysis. *Clin Oral Implants Res* 2013; **24**: 1179–1184.
 37. Loubele M, Bogaerts R, Van Dijck E, Pauwels R, Vanheusden S, Suetens P, Marchal G, Sanderink G, Jacobs R.

- Comparison between effective radiation dose of CBCT and MSCT scanners for dentomaxillofacial applications. *Eur J Radiol* 2009; **71**: 461–468.
38. Marsh H. A case of Roentgen photography. *Br Med J* 1848; **1896**: 1318–1320.
 39. Meloni SM, De Riu G, Pisano M, Cattina G, Tullio A. Implant treatment software planning and guided flapless surgery with immediate provisional prosthesis delivery in the fully edentulous maxilla. A retrospective analysis of 15 consecutively treated patients. *Eur J Oral Implantol* 2010; **3**: 245–251.
 40. Moraschini V, Velloso G, Luz D, Porto Barboza E. Implant survival rates, marginal bone level changes, and complications in full-mouth rehabilitation with flapless computer-guided surgery: a systematic review and meta-analysis. *Int J Oral Maxillofac Surg* 2015; **44**: 892–901.
 41. Nikzad S, Azari A. A Custom-made radiographic template, computed tomography, and computer-assisted flapless surgery for treatment planning in partial edentulous patients: a prospective 12-month study. *J Oral Maxillofac Surg* 2010; **68**: 1353–1359.
 42. Oh T-J, Shotwell JL, Billy EJ, Wang H-L. Effect of flapless implant surgery on soft tissue profile: a randomized controlled trial. *J Periodontol* 2006; **77**: 874–882.
 43. Ozan O, Turkyilmaz I, Ersoy AE, McGlumphy EA, Rosenstiel SF. Clinical accuracy of 3 different types of computed tomography-derived stereolithographic surgical guides in implant placement. *J Oral Maxillofac Surg* 2009; **67**: 394–401.
 44. Rocci A, Martignoni M, Gottlow J. Immediate loading in the maxilla using flapless surgery, implants placed in pre-determined positions, and prefabricated provisional restorations: a retrospective 3-year clinical study. *Clin Implant Dent Relat Res* 2003; **5**: 29–36.
 45. Schlenzka D, Laine T, Lund T. Computer-assisted spine surgery. *Eur Spine J* 2000; **1**: 57–64.
 46. Schneider D, Marquardt P, Zwahlen M, Jung RE. A systematic review on the accuracy and the clinical outcome of computer-guided template-based implant dentistry. *Clin Oral Implants Res* 2009; **4**: 73–86.
 47. Sclar AG. Guidelines for flapless surgery. *J Oral Maxillofac Surg* 2007; **65**: 20–32.
 48. Sennerby L, Rocci A, Becker W, Jonsson L, Johansson LA, Albrektsson T. Short-term clinical results of Nobel Direct Implants: a retrospective multi centre analysis. *Clin Oral Implants Res* 2008; **19**: 219–226.
 49. Sennerby L, Andersson P, Pagliani L, Giani C, Moretti G, Molinari M, Motroni A. Evaluation of a novel cone beam computed tomography scanner for bone density examinations in preoperative 3D reconstructions and correlation with primary implant stability. *Clin Implant Dent Relat Res* 2015; **17**: 844–853.
 50. Sipsos EP, Tebo SA, Zinreich SJ, Long DM, Brem H. *In Vivo* accuracy testing and clinical experience with the ISG Viewing Wand. *Neurosurgery* 1996; **39**: 202–204.
 51. Solomon W. The viewing wand - its introduction and uses. *Br J Theatre Nurs* 1996; **6**: 11–14.
 52. Staffileno H. Significant differences and advantages between the full thickness and split thickness flaps. *J Periodontol* 1974; **45**: 421–425.
 53. Tahmaseb A, De Clerck R, Wismeijer D. Computer-guided implant placement: 3D planning software, fixed intraoral reference points, and CAD/CAM technology. A case report. *Int J Oral Maxillofac Implants* 2009; **24**: 542–546.
 54. Tahmaseb A, De Clerck R, Aartman I, Wismeijer D. Digital protocol for reference-based guided surgery and immediate loading: a prospective clinical study. *Int J Oral Maxillofac Implants* 2012; **27**: 1258–1270.
 55. Tahmaseb A, Wismeijer D, Coucke W, Derksen W. Computer technology applications in surgical implant dentistry: a systematic review. *Int J Oral Maxillofac Implants* 2014; **29**: 25–42.
 56. Tarnow DP, Cho SC, Wallace SS. The effect of inter-implant distance on the height of inter-implant bone crest. *J Periodontol* 2000; **71**: 546–549.
 57. Van de Velde T, Sennerby L, De Bruyn H. The clinical and radiographic outcome of implants placed in the posterior maxilla with a guided flapless approach and immediately restored with a provisional rehabilitation: a randomized clinical trial. *Clin Oral Implants Res* 2010; **21**: 1223–1233.
 58. Van de Velde T, Glor F, De Bruyn H. A model study on flapless implant placement by clinicians with a different experience level in implants surgery. *Clin Oral Implant Res* 2008; **19**: 66–72.
 59. Voulgarakis A, Strub JR, Att W. Outcomes of implants placed with three different flapless surgical procedures: a systematic review. *Int J Oral Maxillofac Surg* 2014; **43**: 476–486.
 60. Walsh PR, Larson SJ, Rytel MW, Maiman DJ. Stereotactic aspiration of deep cerebral abscesses after CT-directed labeling. *Appl Neurophysiol* 1980; **43**: 205–209.