

Immediate loading with dynamic navigation implant surgery

Authors _Dr Jan D'haese, Dr Johan Ackhurst & Prof. Hugo De Bruyn, Belgium

Although osseointegration of dental implants is predictable, thorough preoperative planning is a prerequisite for a successful treatment outcome.^{1,2} Anatomic limitations and prosthetic considerations encourage the surgeon to obtain a very precise positioning of the implants. Historically, standard radiographic imaging techniques (intra-oral and panoramic) were available for investigation of potential implant sites.

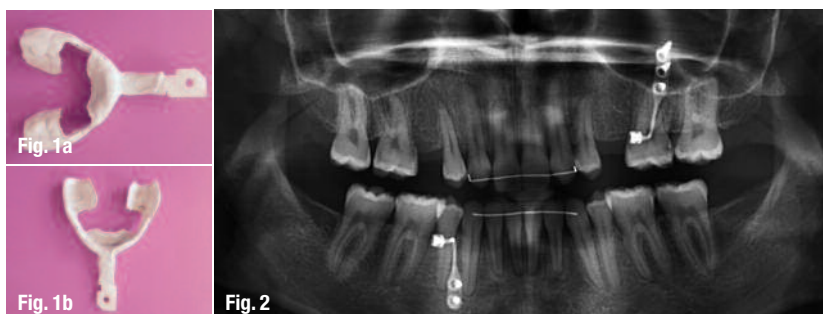Nowadays, it is well known that 3-D CT scans allow for more reliable treatment planning than when only 2-D data is available.³ Transforming the CT scan images into a 3-D virtual image can be achieved using computer software packages, allowing for a 3-D view using CAD technology.³ For years, stereolithographic guided surgery appeared to be the gold standard in computer-guided implant surgery. This technique has been well developed in recent years and several scientific reports have been published regarding accuracy, complications, survival and success.⁴ However, stereolithographic guided surgery has some major disadvantages compared with conventional implant surgery. The surgeon has to rely on a predesigned trajectory planned in the software, without being able to make intra-operative adjustments. In addition, the loss of tactile feeling during preparation and implant placement is a major drawback.

Real-time navigation appears to be a valuable alternative to stereolithographic (static) guided surgery, as it offers the clinician some advantages over the former technique. Using real-time (dynamic) navigation, one can avoid the fabrication of a stereolithographic template, resulting in a less expensive treatment. As navigation is considered a dynamic guided surgery system, changes to the treatment planning (location and size of implants, number of implants, flap or flapless, etc.) can easily be made intra-operatively. Also, the tactile feeling during the drilling procedure, as well as manual control over the implant stability, is still present when using navigation surgery.

Over the last decade, there has been a shift in surgical and prosthetic protocols, resulting in significant reduction in the integration time of a dental implant. This is a logical consequence of the constant improvement of implant characteristics and components simplifying dental implant treatment. Guided surgery using implant simulation software can contribute to better treatment planning, as it provides a preoperative view of the anatomical structures related to the future prosthodontics.⁵ This fact could make immediate loading procedures easier, and allows the clinician to know in advance the potential location and dimension of the future restoration(s). Many guided surgery procedures result in the absence of a flap design. Minimising the surgical flap can have advantages for soft-tissue healing and patient comfort.⁶ However, it has been shown that flapless free-hand surgery, regardless of surgical experience, leads to malpositioning of implants and consequently to bone perforations and dehiscences.⁷ This finding suggests that when using free-hand flapless surgery additional guidance during preparation of the implant bed and during implant placement is required. For this reason, navigation surgery can become an important tool in dental implantology, as it benefits from the advantages

Figs. 1a & b _The NaviStent surgical stent.

Fig. 2 _Pre-op panoramic image.



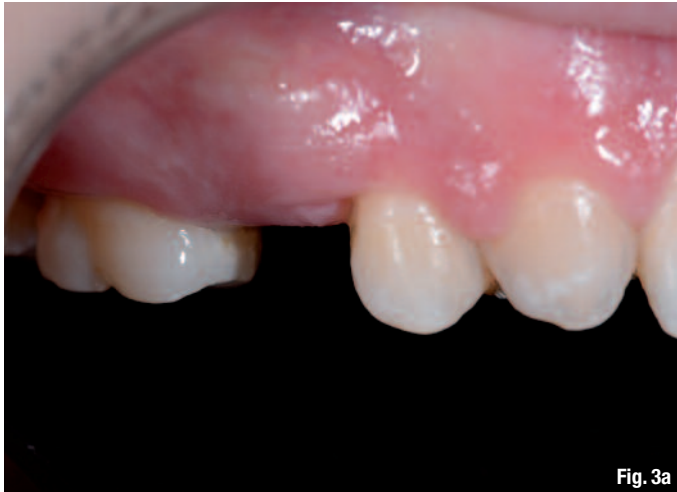

Fig. 3a

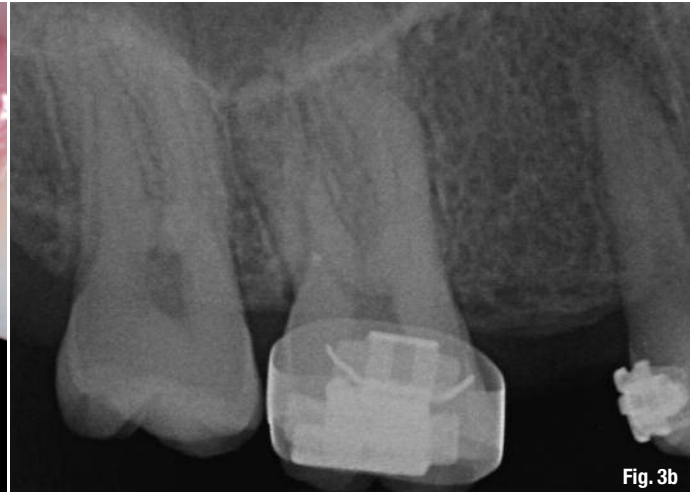

Fig. 3b

of using stereolithographic guided surgery and overcomes some important drawbacks of stereolithographic-involved procedures.

Case presentation

The patient treated was a 21-year-old female consulting the dental office for replacement of both second premolars in the maxilla, at regions #15 and 25. The patient was in good general condition and a non-smoker. She had been treated before at the orthodontic department at Ghent University Hospital because of multiple dental agenesis. Intra-oral examination revealed the absence of both lateral incisors and second premolars in the maxilla and both second premolars in the mandible. Periodontal screening showed no signs of pathology. The bone anchors used during the orthodontic treatment were still present in the second and fourth quadrants. Treatment involved placement of two dental implants in the edentulous regions of the maxilla. Both implants were to be restored with two provisional crowns within 12 hours of implant placement (immediate loading).

Preoperatively, an impression of the dental arch was taken using an irreversible hydrocolloid (Cavex CA37, fast set, Cavex Holland) to fabricate a diagnostic cast. This cast was used as a model for the moulding of the surgical stent; hereafter called NaviStent (Figs. 1a & b). The NaviStent served as a scanning template and was also worn by the patient during the surgery. Afterwards, the patient was sent for a CBCT scan with the NaviStent in place (Figs. 2, 3a & b, 4a & b).

Planning procedure

A standard CBCT scan was performed according to the procedure outlined in the Navident scanning protocol from ClaroNav. Cone beam images were taken with a Planmeca ProMax 3D Max (Planmeca) with a flat-panel detector and isotropic voxels. The field of view used for this case was 50 mm x 100 mm and a voxel size of 200 μ m. The exposition parameters were 96 kV and 10 mA. Care was taken to align the field of view with the jaw and the radiographic tracker, which was situated anterior of the jaw.

Figs. 3a & b Pre-op image of region #15 and a lateral photograph.

Figs. 4a & b Pre-op image of region #25 and a lateral photograph.

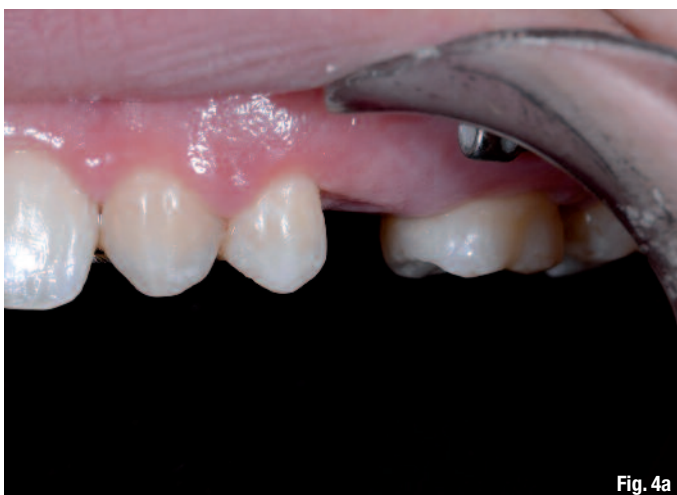

Fig. 4a

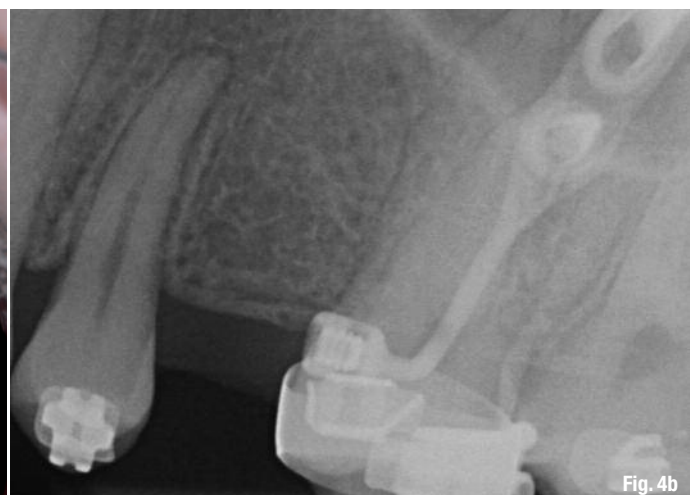

Fig. 4b

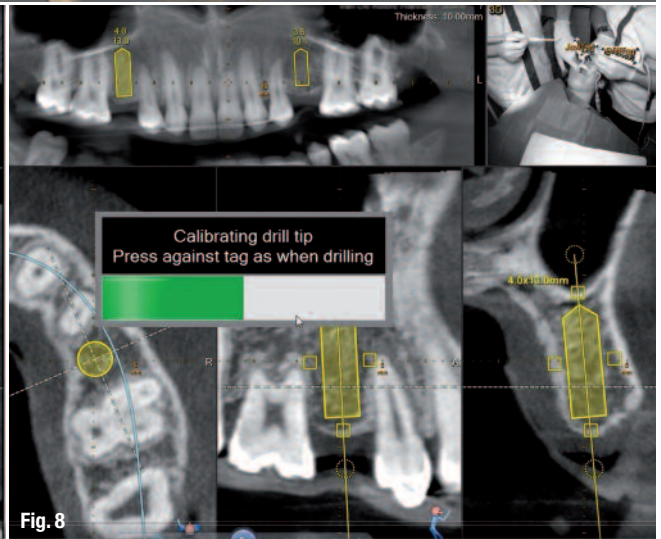
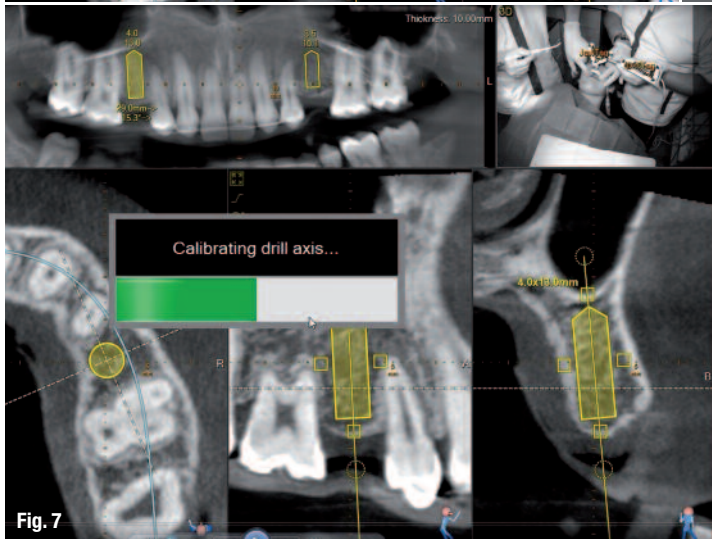
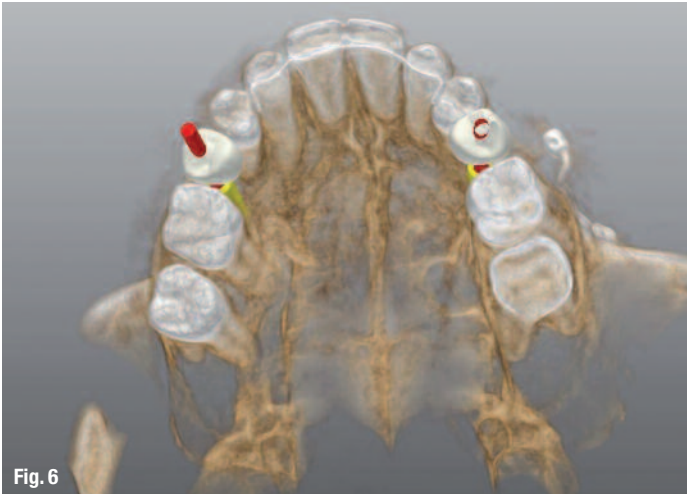
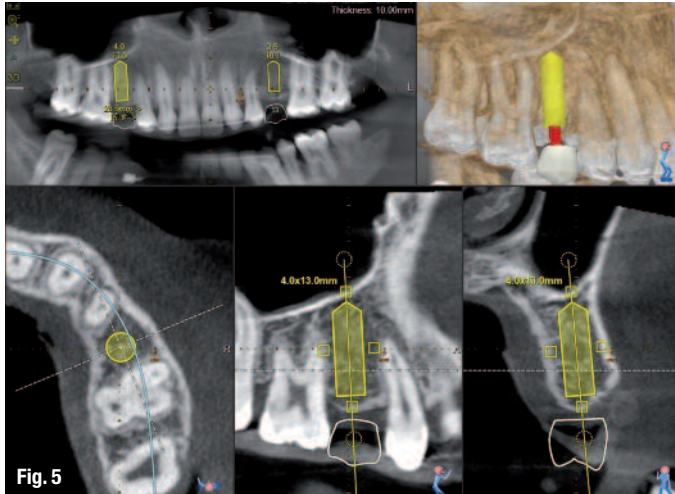


Fig. 5_ Planning in Navident.
Fig. 6_ Planning in Navident.
Fig. 7_ Calibration of the drill axis.
Fig. 8_ Calibration of the drill tip.
Fig. 9_ Surgical guidance using Navident.

All images were carefully reviewed and subsequently the CBCT images were converted into DICOM files and transformed into a 3-D virtual model using the Navident software system. The clinician who placed the virtual implants in the virtual 3-D model also performed the actual surgeries.

The potential locations for implant placement and corresponding implant lengths and widths were planned in a prosthetically driven manner. A distance of at least 3 mm from the neck of the implant to the gingival zenith was applied, allowing the biological width to create a connective tissue contour around the abutments (Figs. 5 & 6).

Surgical procedure

The surgery was performed under local and regional anaesthesia. Appropriate aseptic and sterile conditions were established to prevent postoperative infections. Before the start of the intervention, the NaviStent was placed over the remaining teeth. It was primarily fixated using the undercuts of the remaining teeth and additionally by application of a denture adhesive (Corega, GlaxoSmithKline Consumer Healthcare).

Before starting the osteotomies, the drilling axis of the handpiece used during the surgical procedure was calibrated. The osteotomies were prepared at a maximum of 500 rpm using the Navident naviga-

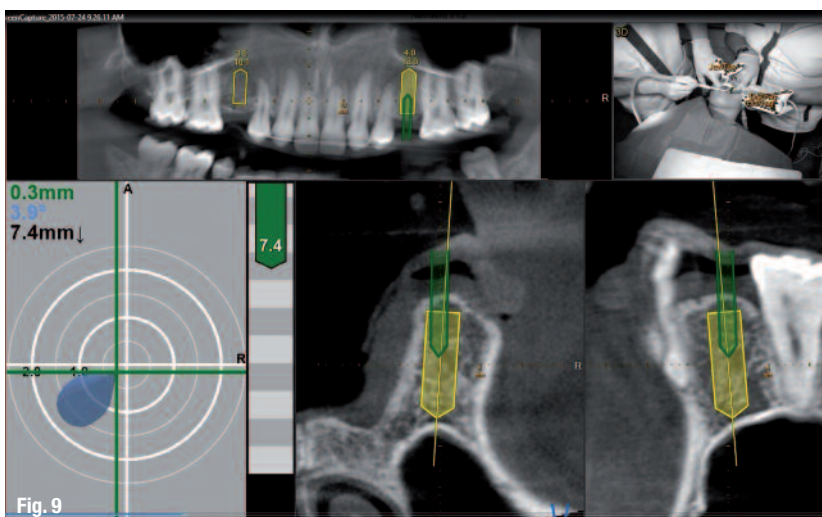

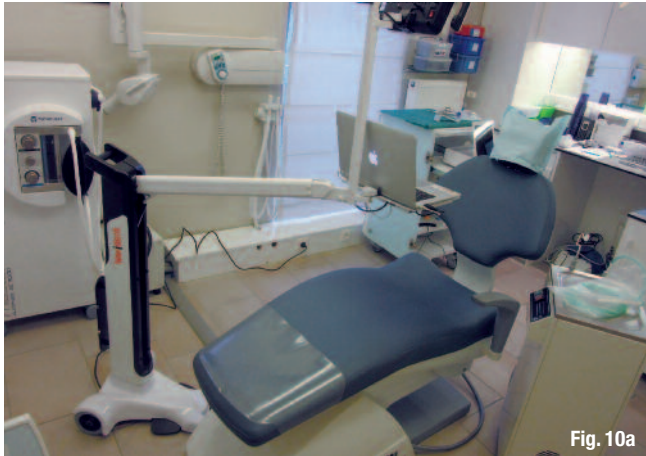


Fig. 10a

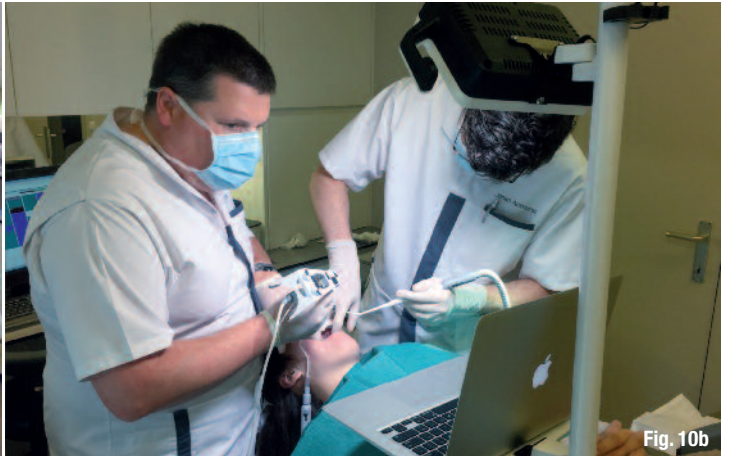

Fig. 10b

tion system to guide the drilling procedure in real time by indicating the desired drilling pathway on the computer screen. Prior to the use of each new drill, a calibration process was performed (Figs. 7–9) in order to determine the exact location of the drilling tip. No punching of the gingival tissue was performed prior to the preparation of the implant sites. Before placement of each implant, an extra calibration procedure was performed in order to be able to track the implant itself also in real time during insertion. This means that both the osteotomy preparation and the implant placement process are tracked in real time. The Navident tracking sys-

tem uses an on-screen visual representation of the surgical area and auditory cues to aid the clinician (Figs. 10a & b). Two XPEED AnyRidge implants (Megagen) were installed. At region #15, an implant of 4mm in length and 13mm in diameter was placed, whereas at region #25 an implant of 10mm in length and 3.5mm in diameter was placed (Figs. 11a & b & 12). After completion of the dental implant placement, a crown-lengthening procedure was performed in the anterior maxillary region in order to ameliorate the aesthetic outcome. It is beyond the purpose of this report to provide any detail regarding this procedure.

Figs. 10a & b _Surgical guidance using Navident.

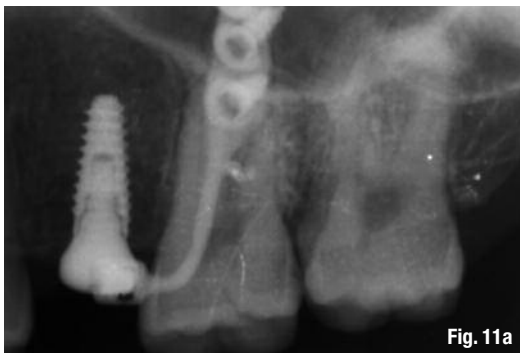

Fig. 11a

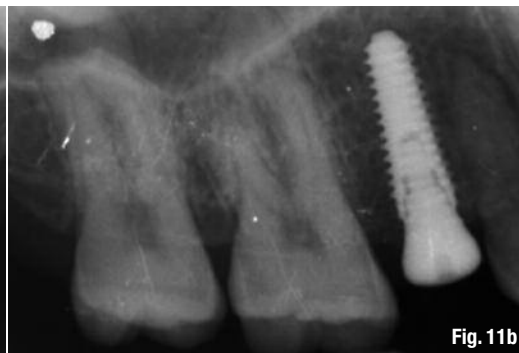

Fig. 11b

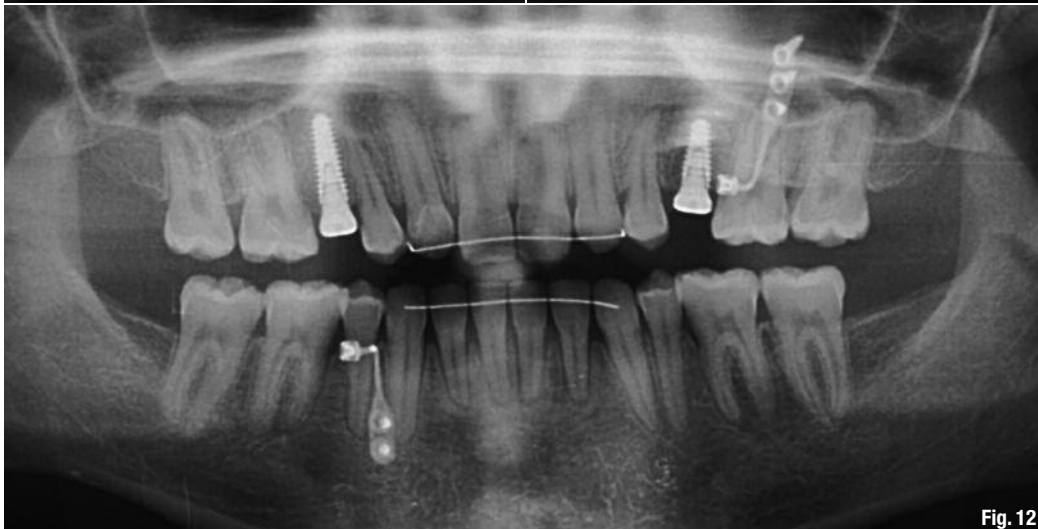


Fig. 12

Figs. 11a & b _Post-op image of regions #15 and 25.

Fig. 12 _Post-op panoramic image.

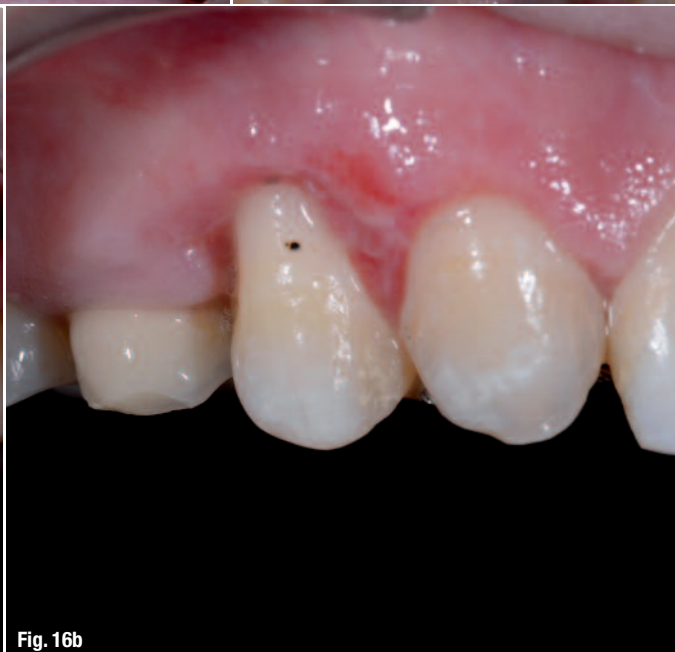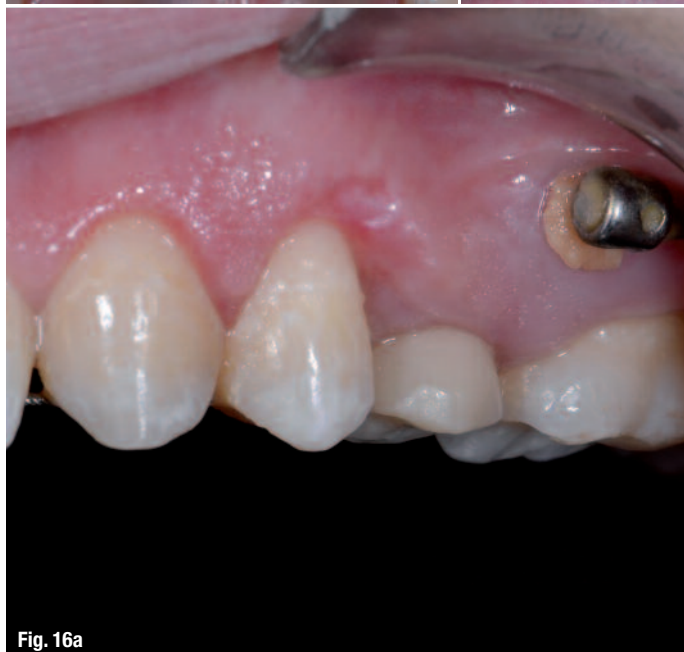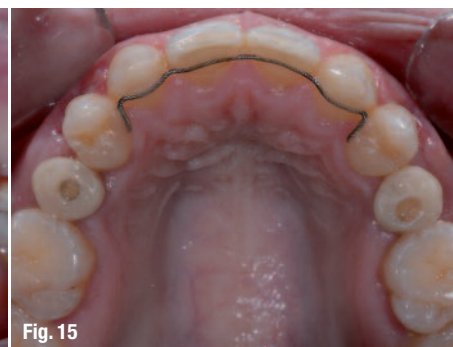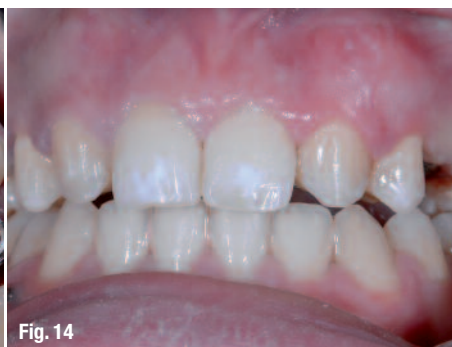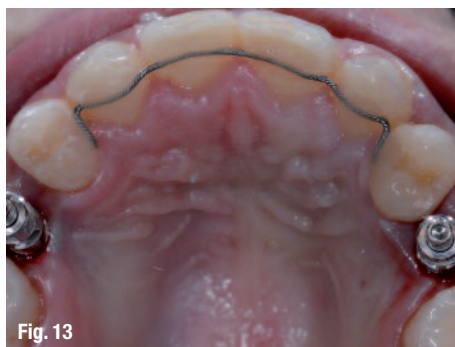


Fig. 13 _Post-op photograph of the maxillary occlusal surfaces.

Fig. 14 _Post-op frontal photograph.

Fig. 15 _Post-op photograph of the maxillary occlusal surfaces (post-loading).

Figs. 16a & b _Post-op lateral photographs of the restorations in regions #15 and 25.

_Prosthetic procedure

Immediately after implant placement, impression copings (Megagen) for an open-tray impression were screwed on to the implants and hand torqued (Fig. 13). An impression was taken at implant level using a silicone material (Permadyne Penta H, 3M ESPE Dental) in a plastic Position Tray (3M ESPE Dental). Within 8 hours, two temporary screw-retained acrylic teeth were delivered to the patient and connected to each of the implants. The acrylic teeth were designed based on temporary titanium abutments. Occlusion and articulation were checked and corrected wherever necessary. All superstructures were hand torqued to a maximum of 15 Ncm. No cantilevers were allowed on the provisional structures in order to avoid extensive non-axial forces. Postoperatively, the patient received a prescription for antibiotics (amoxicillin 1,000 mg, b.i.d., four days), non-steroidal anti-inflammatory drugs (ibuprofen 600 mg, t.i.d.) and a mouthwash (chlorhexidine 0.12%, b.i.d.). After one week, a post-operative visit was scheduled. No signs of infection or inflammation were present and healing was uneventful (Figs. 14 & 15).

_Conclusion

With a two-week postoperative follow-up, this was the first immediate loading procedure based on the Navident navigation surgery system. The patient reported no pain or swelling associated with the dental implant procedure. Further post-operative results are being tracked and reported as part of a pilot study being conducted at Ghent University (Figs. 16a & b).

Editorial note: A list of references is available from the publisher.

_contact

cone beam

Dr Jan D'haese
Ghent University Hospital
De Pintelaan 185
9000 Gent
Belgium

Jan.dhaese@ugent.be